REPRODUCTIVE BIOLOGY

ORIGINAL PAPER

Histology of salmonid testes during maturation

Katarzyna Dziewulska[1], Józef Domagała
Department of General Zoology, University of Szczecin, Poland

Received: 20 August 2002; accepted: 16 December 2002

SUMMARY

The commonly applied classification systems of fish gonad maturity divide the maturation process into certain stages. However, the scales do not entirely reflect the continuity of the maturation process. Based on light microscope observations, the paper describes a comprehensive pattern of testicular transformations during maturation. The study was carried out on precocious underyearling and 1-year-old males of sea trout (*Salmo trutta* m. *trutta* L.), 1-year-old males of salmon (*Salmo salar* L.), and males of brown trout (*Salmo trutta* m. *fario* L.) aged from 7 months to 4 years. A total of 821 gonads collected during all seasons of the year were examined. The fish were fixed in Bouin's fluid. Histological slides of the mid-part of the gonad were made using the standard paraffin technique. The 3-6 μm sections were stained with Heidenhain haematoxylin. Histological changes of testes during maturation were similar in the three species studied. Immature and resting gonads contained type A spermatogonia in lobules only. The appearance of cystic structures containing type B spermatogonia in the lobules signalled the beginning of the sexual cycle in male gonads. Type B spermatogonia underwent synchronous mitotic divisions resulting in an increase in the total number of spermatogonia. As the spermatogenesis

[1]Corresponding author: Department of General Zoology, University of Szczecin, ul. Felczaka 3a, 71-412 Szczecin, Poland; e-mail: katarzyna.dziewulska@univ.szczecin.pl

continued, the gonads showed a gradual increase in the number of cysts containing cells at all the spermatogenetic stages: type B spermatogonia, primary and secondary spermatocytes, spermatids, and spermatozoa. The well-formed spermatozoa were released to the lobule lumen once the Sertoli cells and spermatozoa connections broke up and the cyst disappeared. This was a continuous process observed throughout the spawning season. The spermatozoa were moved to the efferent duct. While some of the germ cells were completing spermatogenesis, the lobules contained less and less cysts with type B spermatogonia, primary and secondary spermatocytes, and spermatids; eventually all the cells completed spermatogenesis. At the end of maturation, vacuoles, up to 18.9 μm in final diameter (brown trout), appeared in the Sertoli cells. The vacuoles were visible in the lobule wall epithelium for a prolonged period of time. In most salmonid individuals examined, the reproductive cycles were observed to overlap. In some fish, the preparation for another cycle began very early, i.e., at the and of preceding spermatogenesis, which had not been observed before. Gonad maturation in some males was incomplete. *Reproductive Biology 2003 3(1): 47-61* .
Key words: spermatogenesis, precocious, incomplete maturation, Salmonidae

INTRODUCTION

Numerous authors have usually limited their descriptions of the fish reproductive cycle to listing the maturity stages of gonads they examined. A number of classification systems to assess male gonad maturity have been developed. Usually these systems suggested the division of the gonad maturation process into five to nine stages. Some classification scales are regarded as universal, while others have been established for certain species only. In addition, they differ in the criteria they are based upon. Some authors emphasize macroscopic criteria (external appearance of the gonad) [6, 15, 31, 32], while others focus on microscopic (presence of specific spermatogenic cells) [3, 11, 13, 14] or physiological characteristics of the testis (serum protein, sex steroid level) [5, 31]. Certain scales employ several criteria to distinguish particular stages [22, 23, 29].

Cytology-based classification systems provide the most accurate description of transformations taking place in the gonads. The papers describing consecutive maturity stages lack adequate presentation of the continuity of the maturation process. Therefore, the objective of this study was to present a full description of histological changes during salmonid testes maturation.

MATERIAL AND METHODS

The study was carried out on 932 young-of-the-year and 250 1-year-old males of sea trout (*Salmo trutta* m. *trutta* L.), 145 1-year old salmon (*Salmo salar* L.) males, and 169 males of brown trout (*Salmo trutta* m. *fario* L.) aged from seven months to four years.

The sea trout were harvested, in all the seasons of the year, within 1992-2000, from ten Western Pomeranian streams located in vicinity of Szczecin. The detailed data on stocking procedures and the fish involved are presented in Dziewulska [9]. The brown trout were collected, in all seasons of the year, within 1995-2000, from the Rudzianka and Chojnówka streams situated near Szczecin. The data on fish origin are presented in Domagała and Dziewulska [8]. Salmon juveniles had been purchased, within October-December 2001, from the Aquamar Fish Farm at Miastko. The age of the sea trout and salmon individuals was known from the authors' own stream stocking experiments or culture, while the age of the brown trout was determined by examining their scales. Selected parameters of the fish harvested are presented in table 1.

The fish, after they had been sacrificed, were fixed in Bouin's fluid and the testes were dissected. The gonads intended for histological examination were selected based on their external appearance and on the gonadosomatic index (GSI). Microscopic examinations were involved most of the maturing/mature gonads and a few juvenile ones. A total of 821 gonads were examined (tab. 1). Histological slides were made using the standard paraffin technique; tissue samples were collected from the mid-part of the gonad. The 3-6 μm sections were stained with Heidenhain haematoxylin. They were examined under a Zeiss Jenaval microscope.

Table 1. Selected parameters (mean±SD) of harvested salmonid males

Specimen	Age of fish [years]	No. of males harvested	No of males used in histological assays	Fish fork length [cm]	Fish weight [g]	Fulton condition coefficient
Salmo trutta m *trutta*	0+	932	525	11.20 ± 1.7	18.91 ± 9.0	1.36 ± 0.7
	1+	250	110	10.83 ± 2.8	17.52 ± 13.7	1.15 ± 0.1
Salmo salar	1+	145	65	10.46 ± 1.2	13.85 ± 4.7	1.17 ± 0.1
Salmo trutta m. *fario*	0+	6	6	12.60 ± 2.1	26.25 ± 13.0	1.21 ± 0.1
	1+	74	40	17.20 ± 2.0	57.97 ± 18.5	1.10 ± 0.1
	2+	41	40	21.18 ± 3.4	115.74 ± 58.9	1.04 ± 0.1
	3+	35	26	26.94 ± 3.5	200.90 ± 111.6	0.96 ± 0.1
	4+	13	9	31.87 ± 3.3	365.94 ± 218.8	1.03 ± 0.3

The Leica Qwin computer image analysis programme was used to measure the seminiferous tubule wall height in gonads at different maturity stages. The measurements in a single gonad were taken at a minimum of 50 sites. In addition, the diameter of vacuoles in lobule boundary walls of post-spawning gonads was measured as well. The diameter was a mean of two measurements taken perpendicularly to each other.

In the incomplete maturing gonads, the amount of maturing cells in a section was expressed as a percentage of the transverse gonad section surface area occupied by a group of maturing/mature germ cells. A computer image analysis program was used to measure the transverse gonad section surface area and the areas occupied by the groups of maturing/mature germ cells. For each fish, five different sections were analyzed, with a subsequent averaging of the results.

RESULTS AND DISCUSSION

Histological changes in testes during the reproductive cycle were similar in the three species studied, for which reason the description of gonad maturation presented below summarizes the transformations taking place.

Germ cells in immature and resting gonads are at the type A spermatogonium (SG A) stage. Those cells occur in the gonads throughout spermatogenesis and form a reserve pool of germ cells. They are found, single or in pairs, not connected with cytoplasmic bridges, in the lobules among the Sertoli cells (fig. 1). Throughout the entire salmonid reproductive cycle, the lobule lumen is poorly visible. Before maturation starts, SG A begin intensive divisions. Murza [20] as well as Murza and Khristoforov [23, 25] termed the actively dividing SG A as the light spermatogonia A. They regarded the appearance of those cells in gonads as the earliest signal of the onset of maturation.

The gonads, in which active spermatogenesis is at the initial phase, show the presence of cysts containing type B spermatogonia (SG B). A cyst is formed as a result of spermatogonia being surrounded by the Sertoli cell processes which form a tight sheath [7, 10, 16]. The youngest cysts contain at first two, and later on four cells. The cells undergo incomplete

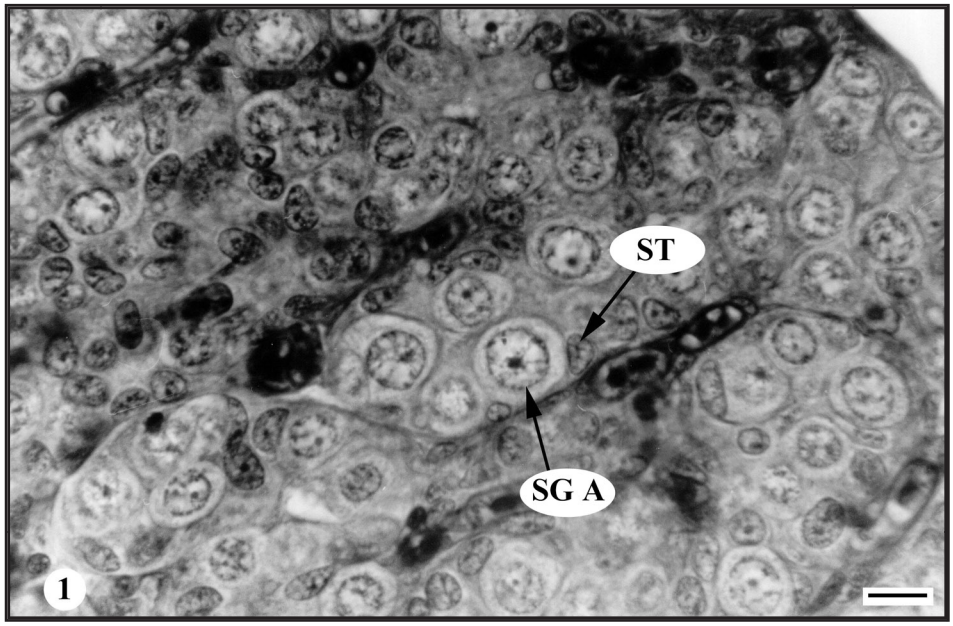

Fig. 1. A fragment of a resting sea trout testis containing type A spermatogonia (SG A) only; Sertoli cells (ST) visible among spermatogonia in lobules; scale bar = 10 μm.

cytokinesis and as a result, further on during maturation, they are connected with cytoplasmic bridges [7, 22, 23]. Their transformations proceed in synchrony. As the gonads mature, more and more cysts containing type B spermatogonia appear; proliferation of type B spermatogonia results in an increasing number of cells in the cysts (fig. 2). The cysts contain up to 64 cells [20, 24]. Among the cysts, adjacent to the lobule boundary wall, there remain only the reserve type A spermatogonia.

When the meiotic division begins type B spermatogonia become the primary spermatocytes (SC I). Gradually, more and more cysts are observed to contain cells undergoing the first meiotic division; some cysts still possessed type B spermatogonia. Type A spermatogonia occur in between the cysts. Having terminated the first meiotic division, cells begin the second division. The second meiotic division is very fast, which explains why secondary spermatocytes (SC II) are very rarely seen. After the meiotic divisions are over, the cysts show the presence of spermatids which undergo

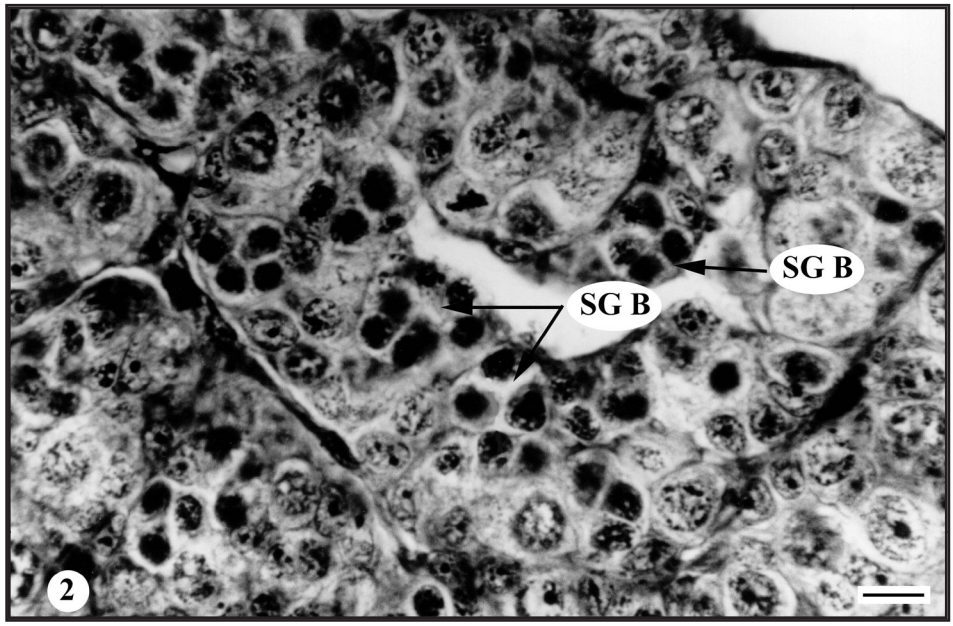

Fig. 2. The testis of sea trout with lobules showing cysts with multiplying type B spermatogonia (SG B); scale bar = 10 μm.

spermiogenesis. Upon completion of spermiogenesis, the cells transform into spermatozoa (SZ). The most advanced cysts show the first spermatozoa to appear. Connections between the Sertoli cells and SZ are broken down [7, 16]. Subsequently, the cyst wall breaks up, whereby the spermatozoa are released into the lobule lumen. The number of SZ released increases as a result of more and more cysts maturing. At the beginning of this stage, the gonad contains cysts with cells at all the preceding phases of spermatogenesis, i.e., type B spermatogonia, primary and secondary spermatocytes, and spermatids. The reserve type A spermatogonia are visible in between the cysts, adjacent to the lobule wall (fig. 3).

As the number of spermatozoa in the lobule lumen increases, spermatozoa are moved into the efferent duct. New batches of cyst-enclosed cells mature gradually. At that time, gonad sections show the cysts to disappear. The lobule boundary wall at that time is considerably stretched and 0.5-1.0 μm thick. The cysts containing type B spermatogonia disappear first, fol-

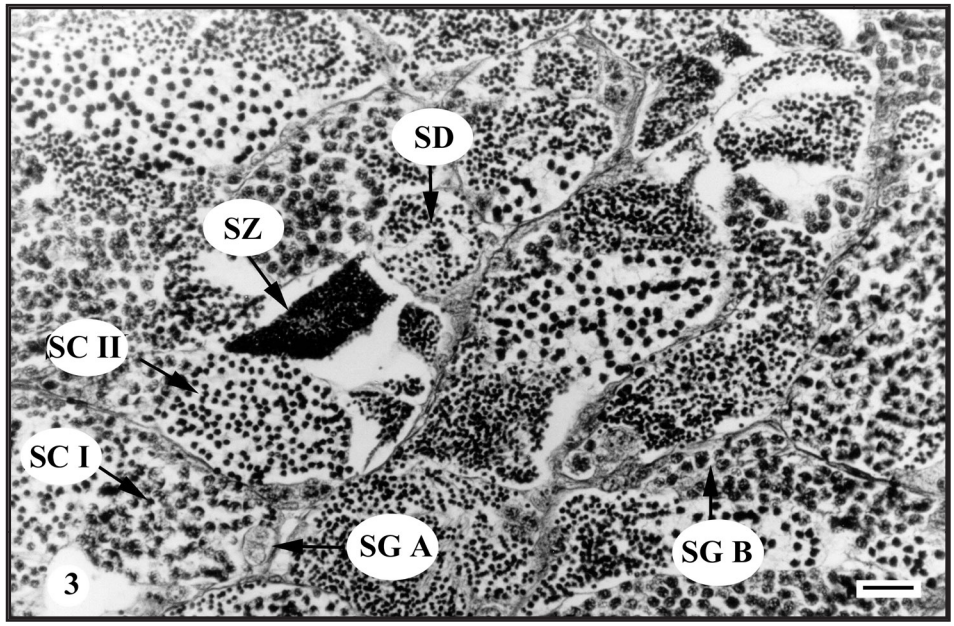

Fig. 3. All spermatogenetic cells in sea trout testicular lobules: type A spermatogonia (SG A); cysts with type B spermatogonia (SG B), primary spermatocytes (SC I), secondary spermatocytes (SC II), spermatids (SD); and spermatozoa (SZ) released into the lobule lumen; scale bar = 20 μm

lowed by those with the primary and secondary spermatocytes and spermatids, until all the cells in a gonad will have finished spermatogenesis (fig. 4). The cystic structures in the gonad become absent. Occasionally, a few cysts may be delayed in their development and, for an extended period of time, the lobules contain single cysts with spermatids, and even spermatocytes. The Sertoli cells that have constituted cyst walls, retract their processes when the wall breaks up. At the end of spermatogenesis, the Sertoli cells produce small vacuoles.

At that stage, some individual males examined showed an unusual condition. The gonads that had just finished spermatogenesis showed the presence of some cells that were getting ready to a new cycle. In the spawning season, in spermatozoa-filled lobules, a few cysts containing up to four type B spermatogonia were observed adjacent to the lobule wall (fig. 5). Other

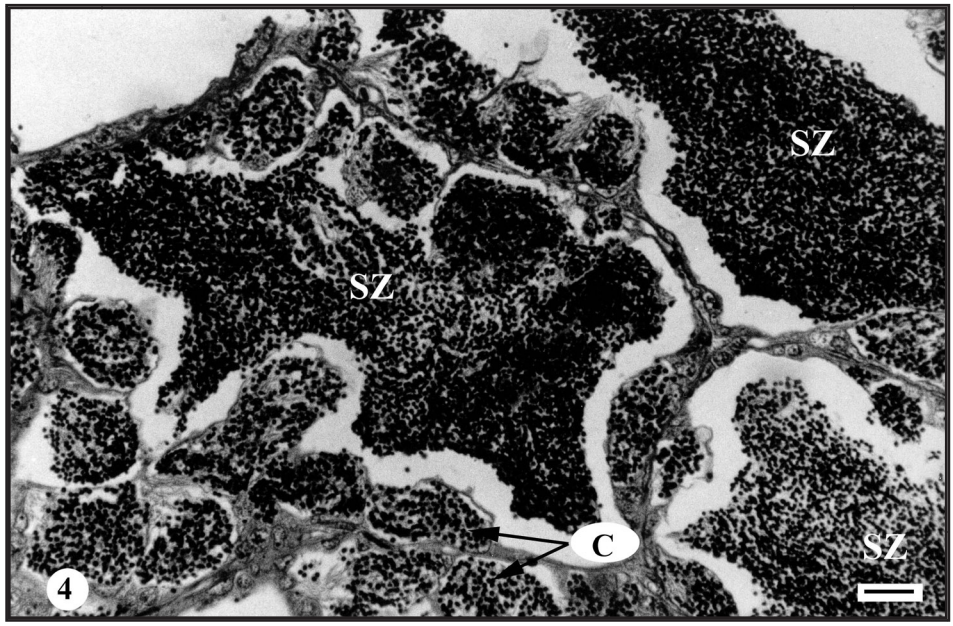

Fig. 4. A spawning salmon testis. The lumen of all the lobules is filled with free spermatozoa (SZ). Cysts (C) with spermatids at the end of spermiogenesis are visible next to the lobule walls; scale bar = 20 μm.

authors reported the overlapping of reproductive cycles in the male gonads much later, in the post-spawning season [1, 17, 20, 23, 24].

The mature spermatozoa are released from gonads during spawning, but some spermatozoa are always left in the testis (fig. 6). They are observed in the gonads for a long period, in some cases until the beginning of a new spermatogenetic cycle. The lobules shrink and the Sertoli cells retract their processes, for which reason the lobule boundary wall becomes higher. In the fish studied, the highest lobule wall epithelium (51.0 μm) was recorded in the brown trout. The spermatozoa remaining in the seminiferous tubules undergo phagocytosis effected by the Sertoli cells (fig. 6). When the seminiferous tubules are being cleaned of spermatozoa, the Sertoli cell vacuoles increase in size considerably, to reach the maximum size of up to 18.9 μm in diameter, recorded in the brown trout (fig. 7). Other authors observed

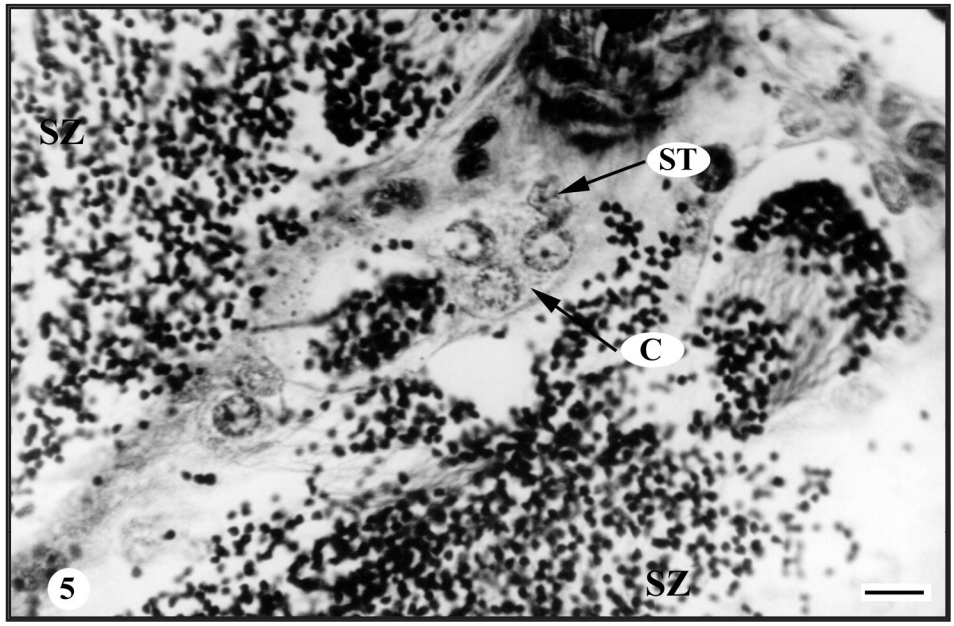

Fig. 5. A brown trout testis with overlapping spermatogenetic cycles: cells of the current cycle have completed spermatogenesis as spermatozoa (SZ) filling lobule lumen, while some cells of the subsequent cycle have already reached the stage of early type B spermatogonia; a cyst (C) of type B spermatogonia with a Sertoli cell (ST) visible next to lobule wall; scale bar = 10 μm.

large vacuoles in different salmonids, e.g., in *Oncorhynchus nerka* [after 13], *Salmo gairdneri* [28], *Salvelinus fontinalis* [11], *Oncorhynchus keta* [12], *Oncorhynchus kisutch* and O. *gorbuscha* [26], *Salmo salar* and *Salmo trutta* m. *trutta* [20, 21]. In pike (*Esox lucius*), the vacuoles are formed by lipid droplets [18]. Similar observations were made after staining gonad sections *Salmo salar* [27] and *Oncorhynchus kisutch* [10]. The vacuole diameter in *Oncorhynchus keta* ranged from 3 to 15 μm [12], reaching 10 μm in *Oncorhynchus kisutch* and *O. gorbuscha* [26]. The vacuoles may remain in the Sertoli cells long after the cycle has been terminated, longer than the remaining spermatozoa, thus signalling the completed maturation process. The vacuoles were visible also in the epithelium of efferent duct wall. In the other authors' opinion, when the vacuoles are not visible and the lobules

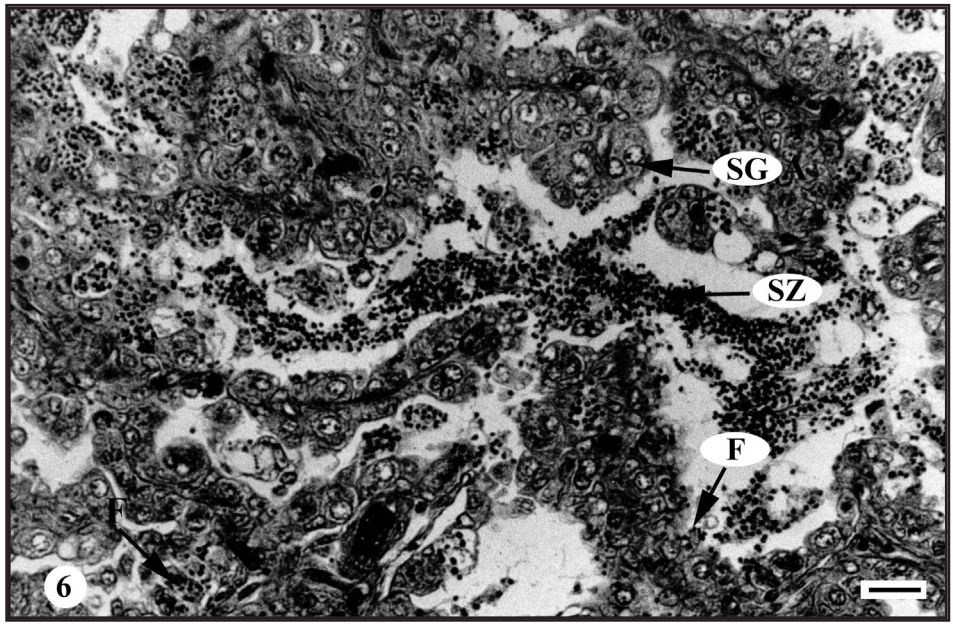

Fig. 6. A spent salmon testis. Some spermatozoa (SZ) remaining in lobule lumen are phagocyted (F) by Sertoli cells. Multiplying type A spermatogonia (SG A) are visible by the lobule walls; scale bar = 20μm.

are cleaned of spermatozoa, the completion of the maturation process may be inferred because of the distended lobules containing peeled off follicular epithelium cells, the numerous distended blood vessels, stretched efferent duct, and thickened gonad walls [23].

The new spermatogenetic cycle is very frequently observed to begin when the remaining spermatozoa are being resorbed, which may take even a few months. Cysts containing SG B, and even SC I, are visible adjacent to the lobule boundary wall. Overlapping reproductive cycles in post-spawning gonads were also reported by Leyzerovich [17], Babushkin [1], Murza [20], and by Murza and Khristoforov [23, 24], as mentioned above. It may be then concluded that the period of rest in gonads after a spermatogenetic cycle has been completed was frequently absent in the fish studied. The sperm remaining in the gonads does not interfere with the beginning of a new cycle; that may start even earlier, when the preceding one is approach-

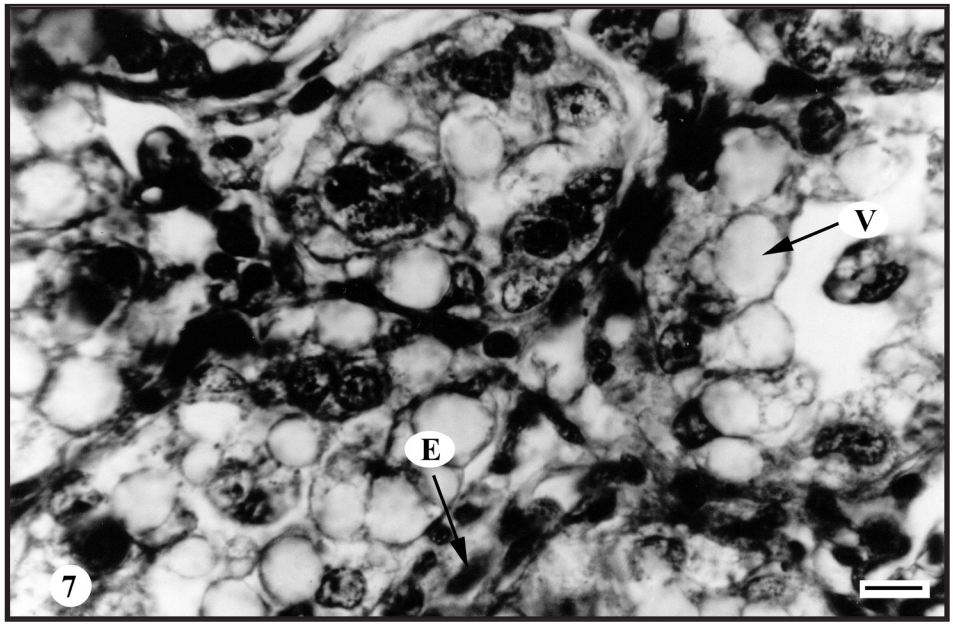

Fig. 7. A brown trout testis after resorption of spermatozoa; lobule wall still contains numerous large vacuoles (V); erythrocytes (E) in distended blood vessels; scale bar = 10μm.

ing its termination. Some authors, however, were of a different opinion. Billard et al. [4] and Billard [2] stated that in brown trout a new cycle could begin in the lobules only after the spermatozoa produced by the preceding spermatogenesis had been resorbed.

Some males, particularly those maturing for the first time, were observed to have produced lower amounts of maturing germ cells in the gonads. In other words, a large part of the germ cells remained inactive, at the type A spermatogonium stage, during the reproductive cycle. This condition has been termed "incomplete maturation". Similar maturation, but involving a narrower range of maturing cells in a section (less than 20% of the section surface area) was reported from salmonids by Murza [19, 21] and by Murza and Khristoforov [22, 23, 24, 25].

The gonad maturation process in the species studied did not show any irregularities. Some males showed early cell preparation for the next

cycle (as early as during termination of the preceding cycle) which has not yet been observed in salmonids. The incomplete maturing fish showed considerable differences in the amount of maturing cells visible on gonad cross-sections and exceptionally large vacuoles were observed in the post-spawning brown trout.

REFERENCES

1. Babushkin JP **1976** Spermatogenesis and reproductive cycles in rainbow trout males (in Russian). *Izvestiya Gosydarstvennogo-issledovatel'skogo instituta oziernogo i rechnogo rybnogo khozyaystva* **117** 51-63.
2. Billard R **1986** Spermatogenesis and spermatology of some telost fish species. *Reproduction Nutrition Development* **26** 877-920.
3. Billard R Escaffre A-M **1975** Identification of spermatogenesis stages in the rainbow trout based on gonad morphology and spermiation (in French). *Bulletin Francais de Pisciculture* **47** 110-116.
4. Billard R Richard M **1982** Inhibition of spermatogenesis and vitellogenesis in rainbow trout by hormonal additives in the diet. *Progressive Fish Culturist* **44** 15-18.
5. Borchard B **1978** Studies on the rainbow trout (*Salmo gairdneri* Rich.). I. Correlation between gonadal development and serum protein pattern. *Annales de Biologie Animale Biochemie Biophysique* **18** 1027-1034.
6. Demel K 1**947** *Biology of Baltic fish* (in Polish). Morski Instytut Rybacki, Gdynia, Poland.
7. Detlaf TA **1982** *Problems of developmental biology. Contemporary problems of spermatogenesis* (in Russian). Nauka, Moskva, Russia.
8. Domagała J Dziewulska K **2002** Sexual cycle of male brown trout *(Salmo trutta* morpha *fario* L.*)* inhabiting streams in the environs of Szczecin (in Polish). *Acta Biologica University of Szczecin* **8** 5-14.
9. Dziewulska K **2001** Spermatogenesis in the sea trout *(Salmo trutta m. trutta L.*) parr in Western Pomerania (in Polish). Ph. D. Thesis, University of Szczecin.
10. Grier HJ Linton JR Leatherland JF de Vlaming VL **1980** Structural evidence for two different testicular types in teleost fishes. *The American Journal of Anatomy* **159** 331-345.
11. Henderson NE **1962** The annual cycle in the testis of the eastern brook trout *Salvelinus fontinalis* (Mitchill). *Canadian Journal of Zoology* **40** 631- 641.
12. Hiroi O Yamamoto K **1968** Studies on the maturation of salmonid fishes – I. Changes in the testis of the masu salmon, *Oncorhynchus masou*, during anadromous migration. *Bulletin of the Faculty of Fisheries Hokkaido University* **19** 173-184.
13. Hiroi O Yamamoto K **1970** Studies on the maturation of salmonid fishes – II. Changes in the testis of the chum salmon, *Oncorhynchus keta*, during anadromous migration. *Bulletin of the Faculty of Fisheries Hokkaido University* **20** 252-263.

14. Jones JW **1940** Histological changes in the testis in the sexual cycle of male salmon parr (*Salmo salar* L. juv.). *Proceedings of the Royal Society of London. Ser. B* **128** 499-509.
15. Jones JW Orton JH **1940** The pedogenetic male cycle in *Salmo salar* L. *Proceedings of the Royal Society of London. Ser. B* 1**28** 485-498.
16. Le Gac F Loir M **1999** Male Reproductive System, Fish. In *Encyclopedia of Reproduction*, **3** pp 21-30. Eds Knobil E Neill JD. Academic Press.
17. Leyzerovich KhA **1973** On dwarfed males during artificial reproduction of the Atlantic salmon, *Salmo salar* L (in Russian). *Voprosy Ikhtiolgii* **13** 460-470.
18. Marshall AJ Lofts B **1956** The Leydig-cell homologue in certain teleost fishes. *Nature* **177** 704-705.
19. Murza IG **1976** A study on the testicular development in the young-of-the-year Neva salmon, grown at various temperatures (in Russian). *Sbornik nauchnykh trudov. Gosydarstvennyj nauchno-issledovatel'skiy institut oziernogo i rechnogo rybnogo khozyaystva* **112** 113-117.
20. Murza IG **1983** Spermatogenesis and reproductive cycle of male Atlantic salmon, *Salmo salar* L. 2. Seasonal dynamics of spermatogenesis and reproductive cycle of dwarfed and intermediate salmon males in various parts of the distribution range (in Russian). *Sbornik nauchnykh trudov. Gosydarstvennyj nauchno-issledovatel'skiy institut oziernogo i rechnogo rybnogo khozyaystva* **200** 78-106.
21. Murza IG **1985** The rate of sexual maturation of sea trout in the Baltic basin (in Russian). *Sbornik nauchnykh trudov. Gosydarstvennyj nauchno-issledovatel'skiy institut oziernogo i rechnogo rybnogo khozyaystva* **228** 136-162.
22. Murza IG Khristoforov OL **1983** Spermatogenesis and reproductive cycle of male Atlantic salmon, *Salmo salar* L. 1. Development of reproductive function and seasonality of testis development (in Russian). *Sbornik nauchnykh trudov. Gosydarstvennyj nauchno-issledovatel'skiy institut oziernogo i rechnogo rybnogo khozyaystva* **200** 50-73.
23. Murza I.G., Khristoforov O.L **1984** Seasonality of gametogenesis and gonad maturity scales in female and male sea trout (in Russian). *Sbornik nauchnykh trudov. Gosydarstvennyj nauchno-issledovatel'skiy institut oziernogo i rechnogo rybnogo khozyaystva* **220** 19-41.
24. Murza IG Khristoforov OL **1984** Dynamics of sexual maturation and certain regularities in the formation of the complex population structure of sea trout, *Salmo trutta* L., in the Kandalaksha Bay (White Sea) coastal water bodies (in Russian). *Sbornik nauchnykh trudov. Gosydarstvennyj nauchno-issledovatel'skiy institut oziernogo i rechnogo rybnogo khozyaystva* **220** 41-86.
25. Murza IG Khristoforov OL **1991** Determining gonad maturity and predicting the age at maturity in the Atlantic salmon and sea trout (in Russian). *Gosydarstvennyj nauchno-issledovatel'skiy institut oziernogo i rechnogo rybnogo khozyaystva,* Leningrad, Russia.
26. Nagahama Y Clarke WC Hoar WS **1978** Ultrastructure of putative steroid-producing cells in the gonads of coho (*Oncorhynchus kisutch*) and pink salmon (*Oncorhynchus gorbuscha*). *Canadian Journal of Zoology* **56** 2508-2519.

27. O'Halloran MJ Idler DR **1970** Identification and distribution of the Leydig cell homolog in the testis of sexually mature Atlantic salmon (*Salmo salar*). *General and Comparative Endocrinology* **15** 361-364.
28. Robertson OH **1953** Sex differentiation in the Pacific salmon *Oncorhynchus keta* (Walbaum). *Canadian Journal of Zoology* **31** 73-79.
29. Sakun OF Butskaya NA **1963** Determination of maturity stage and analysis of reproductive cycles in fish (in Russian). *Polarnyj Institut Rybalovstva i Okeanografii*, Murmansk, Russia.
30. Schulz R Schlaghecke R Blüm V **1981** Variations of gonadal cAMP-content of male and female rainbow trout, *Salmo gairdneri* (Richardson) during the reproductive cycle. *Comparative Biochemistry and Physiology A-Physiology* **70** 53-56.
31. Stuart-Kregor PAC Sumpter JP Dodd JM **1981** The involvement of gonadotropin and sex steroids in the control of reproduction in the parr and adults of Atlantic salmon, *Salmo salar* L. *Journal of Fish Biology* **18** 59- 72.
32. Utoh H **1977** Study of the mechanism of differentiation between the stream resident form and the seaward migratory form of masu salmon, *Oncorhynchus masou* (Brevoort) II. Growth and sexual maturity of precocious masu salmon parr (2). *Bulletin of the Faculty of Fisheries Hokkaido University* **28** 66-73.